

Oleuropein Attenuates Deltamethrin-induced Apoptosis in Rat Cerebellar Purkinje Neurons

Ali Reza khalatbary^{1*}, Behrooz Mohammadnegad², Elmira Ghaffari², Alireza Rafiei³

¹ Molecular and Cell Biology Research Center, Department of Anatomy, Faculty of Medicine, Mazandaran University of Medical Sciences, Sari, Iran.

² Department of Anatomy, Faculty of Medicine, Mazandaran University of Medical Sciences, Sari, Iran.

³ Molecular and Cell Biology Research Center, Department of Immunology, Faculty of Medicine, Mazandaran University of Medical Sciences, Sari, Iran.

Received: 21 Jul 2015

Revised : 19 Aug 2015

Accepted: 17 Sep 2015

Corresponding Author:

Ali Reza khalatbary

Molecular and Cell Biology Research Center, Department of Anatomy, Faculty of Medicine, Mazandaran University of Medical Sciences, Sari, Iran.

Phone: +98 11- 33200894

E-mail: khalat90@yahoo.com

Abstract

Background: Deltamethrin (DM) is a synthetic pyrethroid insecticide that can elicit neurotoxicity, and lead to apoptosis. There is accumulating evidence that oleuropein (OE) has anti-apoptotic effect. This study aimed at determining the DM toxicity and anti-apoptotic effect of OE pretreatment in cerebellar Purkinje neurons.

Materials and Methods: Rats were randomly divided into four groups as follow: DM treated group (12.5 mg/kg; single dose), OE treated group (20 mg/kg per day), DM plus OE treated group, and vehicle group. Sections of cerebellum were taken 24 hours after deltamethrin injection and studied for histopathological and immunohistochemistry assessments.

Results: Further characteristics of degeneration in Purkinje neurons were observed in DM group compared with DM plus OE group. Compared with DM group (9.56 ± 1.69), the positive staining for Bax in Purkinje neurones decreased in DM plus OE group (2.99 ± 0.50) but upper than OE (0.72 ± 0.15) and vehicle (0.57 ± 0.03) groups. Compared with DM group (0.50 ± 0.05), the positive staining for Bcl-2 in Purkinje neurons increased in DM plus OE group (3.29 ± 0.18) but lower than OE (4.38 ± 0.80) and vehicle (5.87 ± 1.93) groups.

Conclusions: Our results suggest that DM induces apoptosis in Purkinje cells which is subsided by oleuropein.

Keywords: Deltamethrin; Oleuropein; Purkinje; Apoptosis

Please cite this article as: Khalatbary A, Mohammadnegad B, Ghaffari E, Rafiei A. Oleuropein Attenuates Deltamethrin-induced Apoptosis in Rat Cerebellar Purkinje Neurons. *Res Mol Med*. 2015; 3 (4): 10-16

Introduction

Pyrethroids are comparatively safe insecticides that have been classified as type I or type II based upon their chemical structure and clinical manifestations of acute exposure (1). Deltamethrin is a type II synthetic pyrethroid insecticide used worldwide as a major class of insecticides in agriculture (2). Acute exposure to deltamethrin can elicit neurotoxicity, characterized by ataxia, loss of coordination, hyperexcitation, convulsions, and paralysis (3). Neurotoxicity of deltamethrin mediated by a series of cellular, molecular, and biochemical cascades, including modification of sodium channels kinetics (4), increasing neurotransmitter release (5), S100 β upregulation (6), induction

of oxidative damage (7), and induction of cytochromeP450s (8). Moreover, in vitro and in vivo studies suggest an important role played by apoptosis in neurotoxicity of deltamethrin (9, 10). Apoptosis or programmed cell death is a key mechanism of neurodegenerative diseases which is triggered by toxins, radiation, hypoxia, oxidative stress, and ischemia-reperfusion, loss of survival /trophic factors, and DNA damage (11). A number of studies revealed that exposure to deltamethrin significantly affected the survival of neurons in rat brain and induced mitochondria-mediated apoptosis (12, 13). The progressive loss of neurons in central nervous system, leads to various neurodegenerative diseases.

In previous decades, a rapidly growing number of natural polyphenol compounds with anti-apoptotic effects have been described. One of the main sources of these molecules is olive oil. Olive oil is a rich source of polyphenolic components such as its main component oleuropein (3, 4 dihydroxyphenylelenolic acid), which are able to cross the blood-brain barrier and which have many beneficial health effects in human (14-16). There is accumulating evidence that attributed the beneficial effects of oleuropein and its derivatives to a variety of biological activities, including free radical scavenging/antioxidant actions, anti-inflammatory effects, anti-carcinogenic properties, and anti-apoptotic properties (16, 17). In this regard, some experimental studies documented that oleuropein

and its derivatives have anti-apoptotic effects against intestinal ischemia/reperfusion injury (18), 6-hydroxydopamine-induced PC12 cell apoptosis (19), and doxorubicin-induced cardiomyopathy (20).

Purkinje cells are among the largest neurons, and are responsible for most of the electrochemical signaling in the cerebellum. These cells can be harmed by a variety of causes such as toxic exposure, autoimmune diseases, genetic mutations, and neurodegenerative diseases.

In the present study, we evaluated the effect of deltamethrin on histopathology and immunohistochemistry of Purkinje neurons, and investigated the role of oleuropein in alleviating the harmful effects of deltamethrin on these cells.

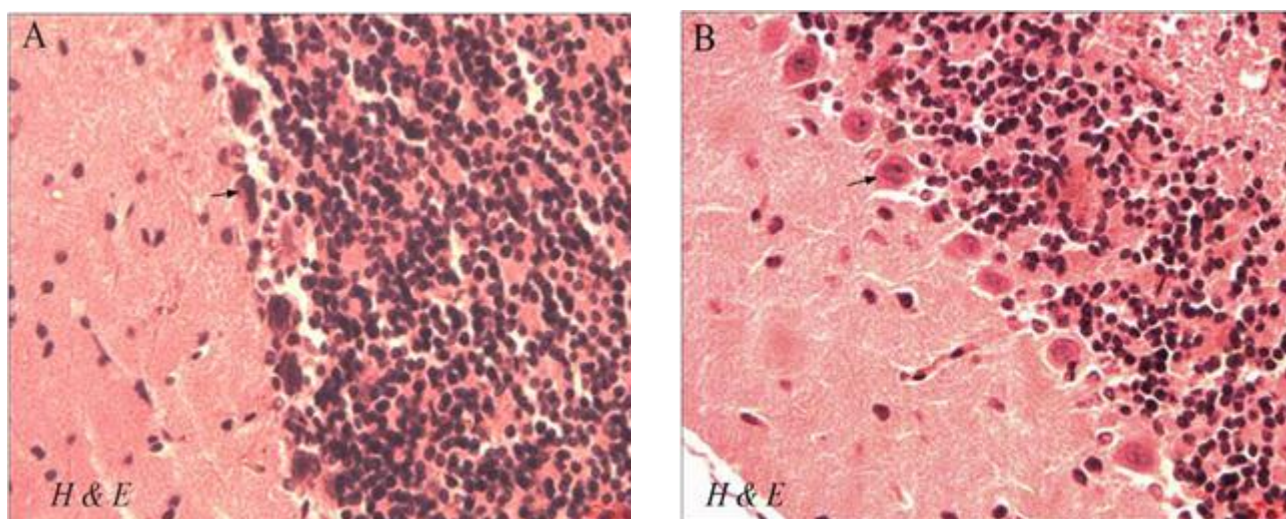


Figure 1. Hematoxylin eosin staining of paraffin sections from the cerebellum of DM (A) and DM+OE (B) treated-rats. Many Purkinje cells showed characteristics of degeneration with pyknosis of nuclei and shrinkage of cytoplasm in DM group (arrow), 400 \times . Little or no signs of degeneration were seen in DM + OE group (arrow), 400 \times .

Materials and methods

Animals

Female adult Sprague–Dawley rats weighing 180–200 g (Pasteur Institute, Tehran, Iran) were used. They were kept under standard conditions and were fed a standard rat chow and drinking water ad libitum throughout the study period.

Experimental groups

The rats were randomly allocated in four groups of five rats each: (I) deltamethrin (DM) treated group (a single intraperitoneal dose of 12.5 mg/kg, 24 hours before sampling; Sigma) (13); (II) oleuropein (OE) treated group (intraperitoneally for 7 days at 20 mg/kg per day; Sigma) (21); (III) DM plus OE treated group was given pretreatment of oleuropein for 7 days at 20 mg/kg per day with a single intraperitoneal dose of 12.5 mg/kg deltamethrin on the seventh day; (IV) vehicle group (the same volume of DMSO).

Histopathological assessment

Cerebellum samples were taken 24 hours after deltamethrin injection (10), fixed in 10% (wt. /vol.) PBS-buffered formaldehyde and embedded in paraffin. Five-micrometer coronal sections were prepared from the paraffin-embedded blocks using microtome. For histopathological assessment, some tissue sections were deparaffinized with xylene, stained with Hematoxylin eosin and cresyl violet, and studied by light microscopy (DME; Leica Microsystems Inc., Buffalo, NY, USA). All the histological studies were performed in a blinded fashion.

Immunohistochemistry

For immunohistochemistry, sections were incubated in goat serum (in order to block nonspecific site), and anti-Bax rabbit polyclonal antibody (1:50 in PBS, vol. /vol., Abcam), or anti-Bcl-2 rabbit polyclonal antibody (1:100 in PBS, vol. /vol., Abcam) overnight at 4 °C. Sections were washed with PBS and then

incubated with secondary antibody conjugated with horseradish peroxidase (goat anti-rabbit IgG peroxidase, Abcam) for 2 hours and demonstrated with diaminobenzidine tetrahydrochloride for 5 minutes. Afterwards, they were dehydrated and mounted. For negative controls, primary antibodies were omitted. For quantitative analysis, immunohistochemical photographs were assessed by densitometry using MacBiophotonics Image J 1.41a software.

Statistical analysis

Statistical analysis was carried out in SPSS (Version 15, Chicago, IL, USA). Results were presented as mean values (\pm SD). The K-S test was used in order to evaluate the normality of the data. Also, the Tukey's multiple comparison tests and the analysis of the variance were used to compare each two groups and data among the groups, respectively. A value of $p < 0.05$ was considered significant.

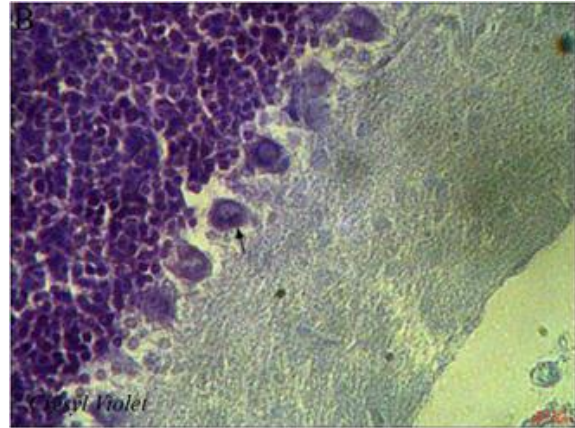
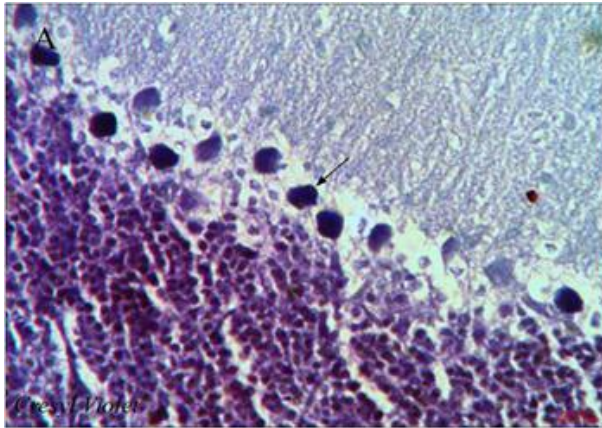


Figure 2. Cresyl violet staining of paraffin sections from the cerebellum of DM (A) and DM+OE (B) treated rats. Many Purkinje cells showed characteristics of degeneration with shrinkage and strong staining of Nissl bodies in DM group (arrow), 400 \times . Little or no signs of degeneration were seen in DM + OE group (arrow), 400 \times .

Results

Histopathological assessments

To observe the morphological characteristics of purkinje cells in rat cerebellum of all experimental groups, the hematoxylin-eosin and cresyl violet staining were used in the present study. Histopathological study showed some degenerative changes with

hematoxylin-eosin staining in purkinje cells (pyknosis of nuclei and shrinkage of cytoplasm) (Figure. 1A) and with cresyl violet staining (shrinkage and strong staining of Nissl bodies) (Figure. 2A) in the cerebellum of DM- treated rats. Whrease, little or no signs of degeneration were seen in other groups (Figure. 1B & 2B).

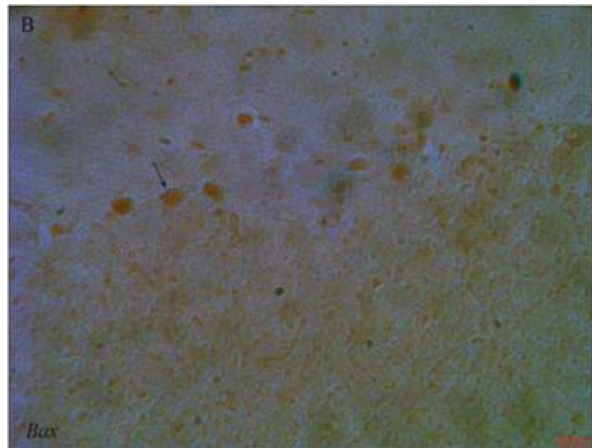
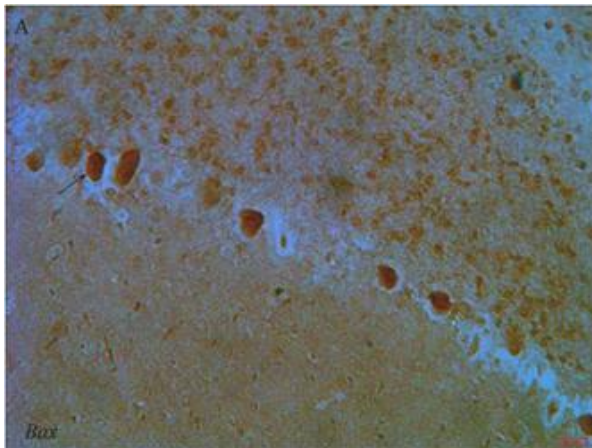


Figure 3. Light photomicrographs show immunohistochemical expression of Bax in DM (A) and DM+OE (B) groups (arrow), 400 \times . The positive staining of Bax is presented by a brown color of cytoplasm.

Immunohistochemistry for Bax and Bcl-2

Figure 3 shows the immunohistochemical staining of Bax. Purkinje cells of the cerebellum from DM

treated-rats exhibited a strong positive staining for Bax (9.56 ± 1.69) (Figure 3A). Oleuropein treatment in DM plus OE treated group reduced the degree of

positive staining for Bax (2.99 ± 0.50) (Figure 3B). Purkinje cells of the cerebellum from OE (0.72 ± 0.15) and vehicle (0.57 ± 0.03) treated-rats showed weak

positive immunoreactions for Bax. Figure 4 shows the immunohistochemical staining of Bcl-2.

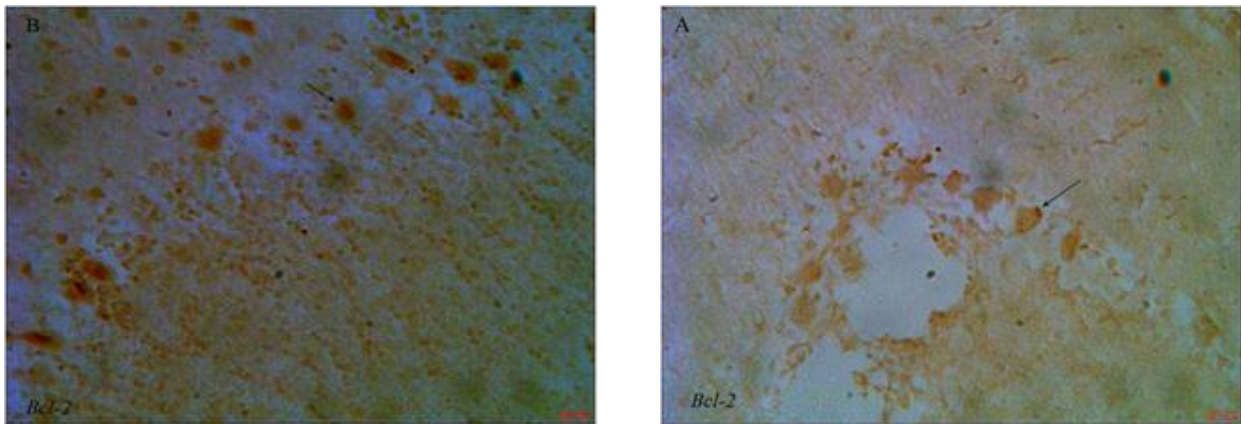


Figure 4. Light photomicrographs show immunohistochemical expression of Bcl-2 in DM (A) and DM+OE (B) groups (arrow), 400 \times . The positive staining of Bcl-2 is presented by a brown color of cytoplasm.

The expression of Bcl-2 was weak in the DM treated-rats (0.50 ± 0.05) (Figure 4A) compared to the up-regulation of Bcl-2 in the DM plus OE treated-rats (3.29 ± 0.18) (Figure 4B).

The expression of Bcl-2 in Purkinje cells of the cerebellum in the OE and vehicle treated-rats were 4.38 ± 0.80 and 5.87 ± 1.93 , respectively.

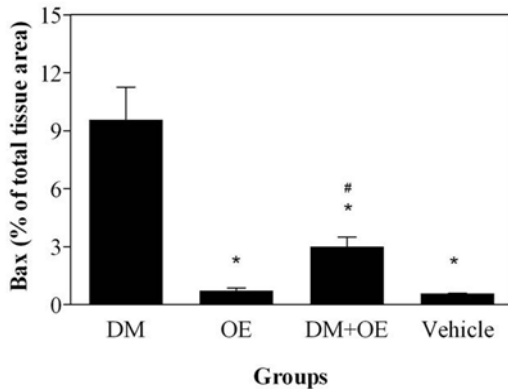


Figure 5. Densitometry analysis of immunohistochemical photomicrographs for Bax. Data are expressed as a percentage of total tissue area. * $P < 0.001$ versus DM group; # $P > 0.05$ versus OE and Vehicle groups. Bars indicate the standard deviations of the mean (SDM).

Quantitative analysis showed that Bax levels significantly reduced in DM plus OE treated-rats compared to DM group (Figure 5). Meanwhile, Bcl-2 levels significantly increased in DM plus OE treated-rats compared to DM group (Figure 6).

Discussion

Neurotoxins are well known risk factors for chronic neurodegenerative diseases. Although molecular

mechanisms involved in the pathogenesis of neurodegenerative diseases remain unclear, oxidative stress, excitotoxicity, inflammation, and apoptosis have been implicated as possible causes on neurodegeneration (22). Apoptosis is a key molecular mechanism of neurodegenerative diseases that is regulated by the Bcl-2 family proteins (22). Among these proteins, Bcl-2 and Bax play anti-apoptotic and pro-apoptotic roles, respectively (23). The ratio of Bax to Bcl-2 determines the cell fate; excess Bcl-2 leads to survival of cells, while Bax induces apoptosis (24, 25). In vitro and in vivo studies have shown that apoptosis is a key mechanism of deltamethrin neurotoxicity which is mediated by altered expression of P53, Bax and Bcl-2, and caspases (9, 13, 26). Caspases are a group of cysteine proteases that play critical roles in apoptosis (27). P53 is a tumor suppressor gene which can induce apoptosis (28). Also, Chen et al. (12) showed that deltamethrin may have an effect on mitochondria-mediated apoptosis of nerve cells in rat brain by altered expression of cytochrome c. The cytochrome c is a small heme protein which is found associated with the inner membrane of the mitochondrion, involved in initiation of apoptosis (29). Deltamethrin causes apoptosis by interaction with Na^+ channels which is leading to calcium overload and activation of the ER stress pathway (9). Results of our immunohistochemical assessment showed that the treatment with deltamethrin increased positive staining for Bax, whereas exhibited a decreased positive staining for Bcl-2 in Purkinje neurons of DM group. These represent a potentially avoidable event by pharmacological interventions. To date, the majority of epidemiological studies involving olive

oil is linked to a decreased incidence of certain types of neurodegenerative diseases such as Alzheimer's (30), multiple sclerosis (31), and aging (32).

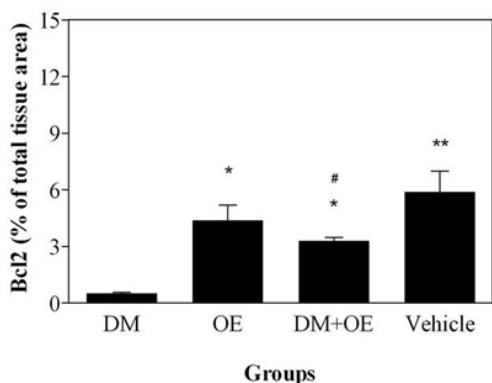


Figure 6. Densitometry analysis of immunohistochemical photomicrographs for Bcl-2. Data are expressed as a percentage of total tissue area. * $P < 0.05$ versus DM group; ** $P < 0.01$ versus DM group; # $P > 0.05$ versus OE and Vehicle groups. Bars indicate the standard deviations of the mean (SDM).

Animal and human studies demonstrated that olive oil phenolic compounds are highly bioavailable, the first requirement for a dietary compound to be a potential neuroprotective effect is that it enters the blood circulation. In this regard, a recent study showed that after administration of olive oil phenols, these were absorbed, metabolized and distributed through the blood stream and across the blood-brain barrier (33). On the other hand, in vitro studies have suggested that anti-apoptotic properties of oleuropein and its derivatives, is a pivotal potential neuroprotective mechanism against neurodegenerative diseases (34). Results of our immunohistochemical assessment showed that treatment with oleuropein reduced positive staining for Bax; while on the contrary, it increased positive staining for Bcl-2 in the DM plus OE treated group. Conversely, oleuropein inhibited the expression of proapoptotic protein Bax and induced that of the antiapoptotic protein Bcl-2, thereby provided the molecular evidence for the neuroprotective activity of oleuropein. In this regard, González-Correa et al. (35) documented that lactate dehydrogenase efflux, as a marker of brain cell death, inhibited in a concentration-dependent manner after 7 days of oral treatment with hydroxytyrosol in rat brain slices subjected to hypoxia-reoxygenation. In vitro study has shown that the olive oil phenolic extract and one of its constituents, gallic acid, exert anti-apoptotic effect against H_2O_2 -induced apoptotic cell death in Hela cells with reduction of time-dependent caspase 9 activity (36). Also, another study documented that incubation of PC12 cells with oleuropein could decrease cell damage and reduce biochemical

markers of apoptotic cell death including activated caspase 3, Bax/Bcl-2 ratio, and DNA fragmentation in 6-hydroxydopamine-induced PC12 cell apoptosis (19). Histological and molecular examinations demonstrated that oleuropein aglycone modulated apoptosis pathway, as shown by tunel staining and Bax/Bcl-2 expressions, in a murine model of intestinal ischemia/reperfusion injury (18). A recent study has shown that oleuropein prevents doxorubicin-induced cardiomyopathy through modulation of kinases such as Akt (20), a serine/threonine-specific protein kinase that plays a key role in apoptosis and cell proliferation (37).

In the present study, it is clear that deltamethrin exposure resulted in alternations of Bax/Bcl-2 expressions and apoptosis in cerebellar Purkinje neurons. Oleuropein pre-exposure provided protection against deltamethrin-induced apoptosis in terms of histopathological and immunohistochemical expression of the pro- and anti-apoptotic protein. In conclusion, this study suggested that oleuropein has modulatory effects against deltamethrin-induced apoptosis in rat cerebellar Purkinje neurons.

Acknowledgements

The authors would like to thank the Medical School for their support.

Authors' Contributions

RA supervised the study, participated in designing and conducting the study. MB and GhE carried out the study and collected the data.

Support/Funding

This study was supported by the Molecular and Cell Biology Research Center (MCBRC), Mazandaran University of Medical Sciences, Sari, Mazandaran, Iran.

Conflict of Interest

The authors declare that they have no conflict of interest in this article.

References

- Soderlund DM, Clark JM, Sheets LP, Mullin LS, Piccirillo VJ, Sargent D, et al. Mechanisms of pyrethroid neurotoxicity: implications for cumulative risk assessment. *Toxicology*. 2002; 171(1):3-59. PMID: 11812616
- Barlow SM, Sullivan FM, Lines J. Risk assessment of the use of deltamethrin on bednets for the prevention of malaria. *Food Chem Toxicol*. 2001; 39(5):407-22. PMID: 11313107
- Wolansky MJ, Harrill JA. Neurobehavioral toxicology of pyrethroid insecticides in adult animals: a critical review. *Neurotoxicol Teratol*. 2008; 30(2):55-78. PMID: 18206347
- Dong K. Insect sodium channels and insecticide resistance. *Invert Neurosci*. 2007; 7(1):17-30. PMID: 1720640

5. Hossain MM, Suzuki T, Sato I, Takewaki T, Suzuki K, Kobayashi H. The modulatory effect of pyrethroids on acetylcholine release in the hippocampus of freely moving rats. *Neurotoxicology*. 2004; 25(5):825-33. PMID: 15288513
6. Patro N, Shrivastava M, Tripathi S, Patro IK. S100beta upregulation: a possible mechanism of deltamethrin toxicity and motor coordination deficits. *Neurotoxicol Teratol*. 2009; 31(3):169-76. PMID: 19118624
7. Yousef MI, Awad TI, Mohamed EH. Deltamethrin-induced oxidative damage and biochemical alterations in rat and its attenuation by Vitamin E. *Toxicology*. 2006; 227(3):240-7. PMID: 16978760
8. Dayal M, Parmar D, Dhawan A, Ali M, Dwivedi UN, Seth PK. Effect of pretreatment of cytochrome P450 (P450) modifiers on neurobehavioral toxicity induced by deltamethrin. *Food Chem Toxicol*. 2003; 41(3):431-7. PMID: 12504175
9. Hossain MM, Richardson JR. Mechanism of pyrethroid pesticide-induced apoptosis: role of calpain and the ER stress pathway. *Toxicol Sci*. 2011; 122(2):512-25. PMID: 21555338
10. Wu A, Liu Y. Apoptotic cell death in rat brain following deltamethrin treatment. *Neurosci Lett*. 2000; 279(2):85-8. PMID: 10674627
11. Sastry PS, Rao KS. Apoptosis and the nervous system. *J Neurochem*. 2000; 74(1):1-20. PMID: 10617101
12. Chen D, Huang X, Liu L, Shi N. Deltamethrin induces mitochondrial membrane permeability and altered expression of cytochrome C in rat brain. *J Appl Toxicol*. 2007; 27(4):368-72. PMID: 17304643
13. Wu A, Ren T, Hu Q, Liu Y. Deltamethrin induces altered expression of P53, Bax and Bcl-2 in rat brain. *Neurosci Lett*. 2000; 284(1-2):29-32. PMID: 10771154
14. Ciceralo S, Lucas L, Keast R. Biological activities of phenolic compounds present in virgin olive oil. *Int J Mol Sci*. 2010; 11(2):458-79. PMID: 20386648
15. Waterman E, Lockwood B. Active components and clinical applications of olive oil. *Altern Med Rev*. 2007; 12(4):331-42. PMID: 18069902
16. Visioli F, Galli C, Galli G, Caruso D. Biological activities and metabolic fate of olive oil phenols. *Eur J Lipid Sci Technol*. 2002; 104:677-84.
17. Visioli F, Poli A, Galli, C. Antioxidant and other biological activities of phenols from olives and olive oil. *Med Res Rev*. 2002; 22(1):65-75. PMID: 11746176
18. Campolo M, Di Paola R, Impellizzeri D, Crupi R, Morittu VM, Procopio A, et al. Effects of a polyphenol present in olive oil, oleuropein aglycone, in a murine model of intestinal ischemia/reperfusion injury. *J Leukoc Biol*. 2013; 93(2):277-87. PMID: 23233730
19. Pasban-Aliabadi H, Esmaili-Mahani S, Sheibani V, Abbasnejad M, Mehdizadeh A, Yaghoobi MM. Inhibition of 6-hydroxydopamine-induced PC12 cell apoptosis by olive (*Olea europaea* L.) leaf extract is performed by its main component oleuropein. *Rejuvenation Res*. 2013; 16(2):134-42. PMID: 23394606
20. Andreadou I, Mikros E, Ioannidis K, Sigala F, Naka K, Kostidis S, et al. Oleuropein prevents doxorubicin-induced cardiomyopathy interfering with signaling molecules and cardiomyocyte metabolism. *J Mol Cell Cardiol*. 2014; 69:4-16. PMID: 24486195
21. Andreadou I, Iliodromitis EK, Mikros E, Constantinou M, Agalias A, Magiatis P, et al. The olive constituent oleuropein exhibits anti-ischemic, antioxidative, and hypolipidemic effects in anesthetized rabbits. *J Nutr*. 2006; 136(8):2213-19. PMID: 16857843
22. Cavallucci V, D'Amelio M. Matter of life and death: the pharmacological approaches targeting apoptosis in brain diseases. *Curr Pharm Des*. 2011; 17(3): 215-29. PMID: 21348825
23. Cory S, Adams JM. The Bcl2 family: regulators of the cellular life-or-death switch. *Nat Rev Cancer*. 2002; 2(9):647-56. PMID: 12209154
24. Crompton M. Bax, Bid and the permeabilization of the mitochondrial outer membrane in apoptosis. *Curr Opin Cell Biol*. 2000; 12(4):414-9. PMID: 10873816
25. Kroemer G. Mitochondrial control of apoptosis: an overview. *Biochem Soc Symp*. 1999; 66:1-15. PMID: 10989652
26. Wu A, Li L, Liu Y. Deltamethrin induces apoptotic cell death in cultured cerebral cortical neurons. *Toxicol Appl Pharmacol*. 2003; 187(1):50-7. PMID: 12628584
27. Wang J, Lenardo MJ. Roles of caspases in apoptosis, development, and cytokine maturation revealed by homozygous gene deficiencies. *J Cell Sci*. 2000; 113(5):753-7. PMID: 10671365
28. Chumakov PM. Function of the p53 gene: choice between life and death. *Biochemistry (Mosc)*. 2000; 65(1):28-40. PMID: 10702638
29. Tafani M, Karpinich NO, Hurster KA, Pastorino JG, Schneider T, Russo MA, et al. Cytochrome c release upon Fas receptor activation depends on translocation of full-length bid and the induction of the mitochondrial permeability transition. *Journal Biol Chem*. 2002; 277(12):10073-82. PMID: 11790791
30. Scarmeas N, Stern Y, Mayeux R, Luchsinger JA. Mediterranean diet, Alzheimer disease, and vascular mediation. *Arch Neurol*. 2006; 63(12):1709-17. PMID: 17030648
31. Materljan E, Materljan M, Materljan B, Vlacic H, Baric'ev-Novakovic Z, Sepcic J. Multiple sclerosis and cancers in Croatia—a possible protective role of the 'Mediterranean diet'. *Coll Antropol*. 2009; 33(2):539-45. PMID: 19662776
32. Battino M, Ferreira MS. Ageing and the Mediterranean diet: a review of the role of dietary fats. *Public Health Nut*. 2004; 7(7):953-8. PMID: 15482624
33. Serra A, Rubió L, Borràs X, Macià A, Romero MP, Motilva MJ. Distribution of olive oil phenolic compounds in rat tissues after administration of a phenolic extract from olive cake. *Mol Nutr Food Res*. 2012; 56(3):486-96. PMID: 22183818
34. Khalatbary AR. Olive oil phenols and neuroprotection. *Nutr Neurosci*. 2013; 16(6):243-9. PMID: 23406576
35. González-Correa JA, Navas MD, Lopez-Villodres JA, Trujillo M, Espartero JL, De La Cruz JP. Neuroprotective effect of hydroxytyrosol and hydroxytyrosol acetate in rat brain slices subjected to hypoxia-reoxygenation. *Neurosci Lett*. 2008; 446(2-3):143-6. PMID: 18809463

36. Erol-Dayi O, Arda N, Erdem G. Protective effects of olive oil phenolics and gallic acid on hydrogen peroxide-induced apoptosis. *Eur J Nutr.* 2012; 51(8):955-60. PMID: 22086301

37. Chen WS, Xu PZ, Gottlob K, Chen ML, Sokol K, Shiyanova T, et al. Growth retardation and increased apoptosis in mice with homozygous disruption of the Akt1 gene. *Development.* 2001; 15(17):2203-8. PMID: 11544177