

Comparison of TNF- α and TGF- β 1 Level in Radicular Cyst and Odontogenic Keratocyst Fluid and its Association with Histopathological Findings

Safoura Seifi ^{1*}, Mohammad Mehdizadeh ², Ghorban Maliji ³, Zahra Sadat Korsavi ⁴, Kamran Nosrati ⁵

¹Department of Oral and Maxillofacial Pathology, School of Dentistry, Babol University of Medical Sciences. Babol, Iran.

²Department of Oral and Maxillofacial Surgery, School of Dentistry, Babol University of Medical Sciences. Babol, Iran.

³Department of Immunology, Faculty of Medicine, Babol University of Medical Sciences. Babol, Iran.

⁴Dentist, School of Dentistry, Babol University of Medical Sciences Iran. Babol, Iran.

⁵Department of Oral and Maxillofacial Surgery, School of Dentistry, Babol University of Medical Sciences. Babol, Iran.

Received: 19 Feb 2013

Revised : 23 Apr 2013

Accepted: 26 Aug 2013

Corresponding Author:

Safoura Seifi

Department of Oral and Maxillofacial Pathology, School of Dentistry, Babol University of Medical Sciences

Phone: +98-112291408

E-mail: sf_seify@yahoo.com

Abstract

Background: TNF- α is a multifunctional proinflammatory cytokine and TGF- β 1 is a secretory protein controlling epithelial proliferation and differentiation. Keratocyst presents an aggressive behavior and a growth mechanism different from that of radicular cyst. In this line, the present study aimed at evaluating TNF- α and TGF- β 1 level and its association with histopathological findings in the two odontogenic lesions of different origins.

Materials and Methods: In this case-control study, aspirated fluid of 15 cases of radicular cyst and 15 cases of keratocyst were investigated using ELISA method. The grade of inflammation and the mean number of blood vessels in three microscopic fields were provided with a magnification of 40 times on microscope slides. T-test, x², Mann Whitney, and Pearson correlation tests were used for the comparison of TNF- α and TGF- β 1 levels in the mentioned lesions and the association between cytokine levels and grade of inflammation and angiogenesis.

Results: TNF- α and TGF- β 1 were observed in aspirated fluid of all radicular cysts and keratocysts. Levels of TNF- α and TGF- β 1 were found to be 6.72 ± 2.985 and 5.882 ± 2.985 respectively in radicular cyst fluid and 24.759 ± 94.849 and 63.38 ± 30.069 in keratocyst fluid; however, no statistically significant difference was observed in terms of TNF- α ($P=0.450$); increasing trend in TNF- α level in radicular cyst and keratocyst was accompanied by increased inflammation and angiogenesis ($P<0.001$ and $P=0.001$).

Conclusions: TNF- α and TGF- β 1 are involved in the pathogenesis of radicular cyst and keratocyst. TGF- β 1 level was higher in radicular cyst when compared with keratocyst; however, TNF- α level was similar in the two lesions. A positive correlation was found between TNF- α level and grade of inflammation and angiogenesis.

Keywords: Radicular cysts; Odontogenic keratocyst; TNF- α ; TGF- β 1; ELISA

Please cite this article as: Seifi S, Mehdizadeh M, Maliji Gh, Korsavi ZS, Nosrati K. Comparison of TNF- α and TGF- β 1 Level in Radicular Cyst and Odontogenic Keratocyst Fluid and its Association with Histopathological Findings. Res Mol Med. 2013; 1 (2): 39-44.

Introduction

Odontogenic keratocyst is the third most common cyst of oral cavity, after the radicular and dentigerous (follicular) cysts, with an origin from remnants of dental lamina in the functional stage; it, therefore, shows a significant growth potential as is called a benign cystic tumor in new WHO classification (1).

Radicular (periapical) cyst is the second most common lesion at the periapical area which is classified into the inflammatory cysts category, accounting for approximately 20% of real odontogenic cysts. The mentioned cyst is created via the penetration of microorganisms' toxin from decayed tooth to periapical area

and an immune defense reaction of the host, growth factor secretion by fibroblasts, and the proliferation of Malassez epithelial rests as well as necrosis of its central area (1). The contents of odontogenic keratocyst include a watery, straw-colored fluid, mostly a serum exudate or a thick white or yellowish cheese like material made of keratin debris. The contents of radicular cyst include a watery, straw-colored fluid to a semi-solid brownish material of paste like consistency along with cholesterol crystals, including the degradation products of inflammatory cells and connective components and different amounts of proteins (immunoglobulin, cytokine, prostaglandin, etc.). The growth mechanism of radicular cyst is different from that of odontogenic keratocyst, and the latter does not usually cause jaw inflammation due to anterior-posterior development (2). Tumor Necrosis Factor alpha (TNF- α) is a proinflammatory cytokine that plays a role in bone resorption, inflammation caused by jaw cysts, and fibroblast activity.

It is secreted by lymphocytes and macrophages and acts as a stimulant for cell apoptosis and necrosis in sensitive and tumoral tissues and as an inducer for the formation of new blood vessels (2). Transforming Growth Factor beta 1 (TGF- β 1) is a secretory protein, controlling epithelial proliferation and differentiation, that binds to extracellular matrix (ECM) and cells and acts as an anti-proliferative factor in epithelial cells and early stages of cancer, and found to have three subgroups including TGF- β 1, β 2, and β 3 (3).

Some studies have reported higher levels of TNF- α in aspirated fluid of radicular cyst compared with residual cysts (4). Few studies have investigated TNF- α level in odontogenic keratocyst and radicular cyst fluids and no research has yet been conducted to compare TGF- β 1 levels in the two mentioned lesions and the association between levels of TNF- α and TGF- β 1 expression. Hence, the present study was carried out to evaluate TNF- α and TGF- β 1 level in the two cysts of different origins and its association with histopathological findings of the lesions.

Materials and Methods

The present case-control study was carried out on cases referring to the Dental School, private clinics and specialty clinics of Faculty of Dentistry of Babol, Sari, Qom, Isfahan and Kashan. Before surgery (enucleation) and removal of radicular cysts and odontogenic keratocysts, fluid content of lesions with clinically differential diagnosis of the mentioned cysts were aspirated through 2-gage syringe from Supa company and were transferred to the immunology laboratory; thick samples as well as those contaminated with saliva and/or blood were excluded from the study and the remaining samples were kept at a temperature of -70 °C until the day of

the experiment. In the cases of which aspiration was performed in other cities, samples were put into an ice container and were transferred to the laboratory. After surgical treatment, oxygenal biopsy obtained in 10% formalin was transferred to the Pathology Department; hematoxylin-eosin staining was performed and diagnosis of radicular cyst (15 samples) and odontogenic keratocyst (15 samples) was confirmed. In cases for which no confirmation was made in the diagnosis of the mentioned cysts, aspirated fluid was excluded from the study.

It should be noted that patients were given informed written consent before participation in the study. In order to conduct the experiment using ELISA method, samples were placed at the room temperature; the cysts contents were then centrifuged, the supernatant was removed and levels of TNF- α and TGF- β 1 were evaluated by KOMA Kits (made in Korea) using sandwich ELISA based on pg/ml in radicular cyst and odontogenic keratocyst. Grade of inflammation and the number of blood vessels were also evaluated in three microscopic fields with a magnification of 40 times per each slide using an optical microscope (Olympus BX41 Japan), the mean of which are presented in table; the association between TNF- α and TGF- β 1 levels and grade of inflammation and number of blood vessels in microscope slides were investigated and the results as well as patients' demographic characteristics (age, gender, tumor location) were transported to SPSS20 statistical software. In order to compare levels of TNF- α and TGF- β 1 expression in the two lesions, t-test, Mann Whitney and X² were applied. Pvalue <0.05 was significant. To determine the relationship between level of TNF- α and TGF- β 1 expression and grade of inflammation and angiogenesis, Pearson correlation was used.

Inflammation was classified in microscopic slides as follows (3).

Grade1: Less than 10 inflammatory cells in three microscopic fields.

Grade 2: 10 to 50 inflammatory cells in three microscopic fields.

Grade3: Greater than 50 inflammatory cells in three microscopic fields. The number of blood vessels was classified as follows (3);

Grade1: Less than 10 blood vessels in three microscopic fields.

Grade2: 10 to 15 blood vessels in three microscopic fields.

Grade3: Greater than 15 blood vessels in three microscopic fields

Results

In this study, aspirated fluid of 15 odontogenic keratocysts and 15 radicular cysts were evaluated. Out

of 15 keratocysts, only four cases were observed with mild inflammation and the rest were found to be

moderate to severe.

Table 1. Frequency distribution of variables (age, gender and lesion location) in adenoid cystic carcinoma and mucoepidermoid carcinoma.

Type of lesion	Adenoid cystic carcinoma	Mucoepidermoid carcinoma	P- value
Age (year)*	52.6 ± 17.2	33.5 ± 18.2	0.002
<i>Gender</i>			
Male	13	7	0.102
Female	8	12	
<i>Lesion location</i>			
Major salivary Gland	5	10	0.060
Minor salivary Gland	16	9	

*(Mean ± SD)

Only three cases of radicular cyst and four cases of odontogenic keratocyst were found with grade I inflammation and number of blood vessels. Although the amount of TNF- α was higher in radicular cyst, the

difference was not statistically significant between the two lesions (P=0.459). Higher level of TGF- β_1 was observed in radicular cyst compared with odontogenic keratocyst (P=0.029).

Table 2. The mean total, intratumoral and peritumoral microvascular density (MVD) in malignant salivary gland neoplas.

MVD (Mean ±SD)	Adenoid cystic carcinoma	Mucoepidermoid carcinoma	P- value
Intratumoral	11.9 ± 5.9	14.47 ± 5.63	0.171
Peritumoral	4.8 ± 2.3	4.63 ± 1.73	0.734
Total	16.6 ± 7.4	19.11 ± 6.44	0.279

Increasing concentrations of TNF- α (pg/ml) in radicular cyst and odontogenic keratocyst showed an increase in grade of inflammation and number of blood vessels (P2= 0.000) (P = 0.001, 0.000).

However, no significant relationship has been observed between levels of TGF- β and grade of inflammation and angiogenesis in radicular cyst and odontogenic keratocyst (P2= 0.67, 0.379) (P1 = 0.82, 0.983). No significant correlation has been found between levels of TNF- α (pg/ml) and TGF- β_1 in radicular cyst (P<0.847) and odontogenic keratocyst (P<0.268). No statistical relationship has been observed between the two lesions in terms of the inflammation grade (P<0.541). However, the difference was found to be significant in terms of angiogenesis, which was higher in radicular cyst as compared with odontogenic keratocyst (P <0.033).

Discussion

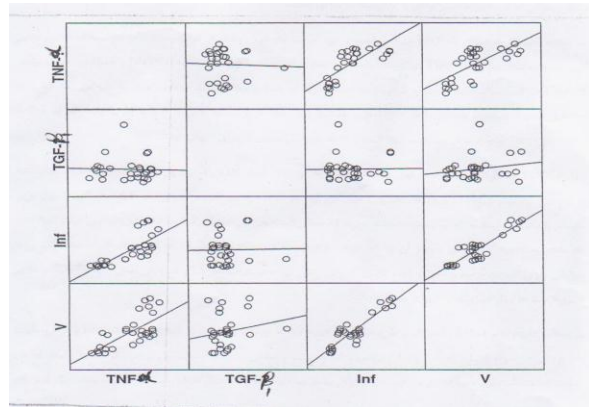
According to the findings of the present study, TNF- α and TGF- β_1 expression was observed in aspirated fluid of radicular cyst and odontogenic keratocyst of all samples and it can be, therefore, concluded that

these cytokines may contribute to the pathogenesis of both odontogenic lesions. Moreover, it is conjectured that some similarities may exist in the growth mechanisms of radicular cyst and keratocyst of two different origins. Although most studies have ascribed radicular growth to increase in osmotic and hydrostatic pressure and keratocyst growth to some factors such as matrix metalloproteinase activity and epithelial proliferation (1, 2, 5), the results of the present study revealed similarities in the growth mechanism between radicular cyst and keratocyst; Ward et al. study also confirms the above findings, so as increased osmotic and hydrostatic pressure is involved in early and intermediate stages of keratocyst and radicular cyst development, while enzymatic factors and epithelial proliferation as well as increased mitotic activity are implicated in the late stages of cyst development (6). In Hayashi et al. study, similarities of a number of cytokines in aspirated fluid and culture medium of keratocyst and radicular cyst were inactive of similar growth mechanism (7), which is in agreement with the results of the mentioned study.

Table 3. Comparison of microvascular density in intratumoral and peritumoral regions of mucoepidermoid carcinoma and adenoid cystic carcinoma.

Type of lesion MVD (Mean ± SD)	Intratumoral	Peritumoral	P- value
Adenoid cystic carcinoma	11.9 ± 5.9	4.8 ± 2.3	0.003
Mucoepidermoid carcinoma	14.47 ± 5.63	4.63 ± 1.73	0.144

Although TNF- α level was higher in aspirated fluid of radicular cyst than keratocyst in the recent study, the difference was not significant. TGF- β_1 level was higher in radicular cyst in comparison with keratocyst. In a study by Jurisic et al., TNF- α level was found to be higher in radicular cyst than keratocyst (8), which is not congruent with findings of the present study. The difference between the results of the two studies seems to be due to the number of keratocysts with mild inflammation, which was found to be 56.3% in Jurisic et al. study (8) and only 4 out of 15 cases in the present study.

**Figure 1.** The mutual relationship between TNF- α and TGF- β_1 and its association with inflammation and angiogenesis in radicular cyst and keratocyst.

TGF- β_1 is a potent fibrogenic cytokine that stimulates collagen synthesis by decreasing proteinase activity and inhibits collagen degradation by increasing proteinase tissue inhibitors (TIMP) activity. In the

current study, increased level of TGF- β_1 has been observed in aspirated fluid of radicular cyst compared with keratocyst, which may be due to increased activity of matrix metalloproteinase-2 and -9, leading to collagen breakdown. Since inflammation and restoration are like a double-edged sword, elevated formation and restoration of collagen tissue is observed in line with higher grades of inflammation in a cyst of inflammatory origin. In Li et al. studies, the role of TGF- β_1 has been confirmed in the proliferation of fibroblasts and confirmed in the proliferation of fibroblasts and fibrogenic effect (9).

In a study by Singh et al. investigating the color and orientation of collagen fibers using Picro-sirius red staining and polarized microscopy in 15 cases of keratocyst, radicular and dentigerous cysts and advanced stages of odontogenesis, the thickness of collagen fibers was reported to be more in radicular cyst and less in other lesions. Fibers' color was yellow-orange in keratocyst and red-orange in radicular and dentigerous cysts. In keratocyst, collagen fibers had a direction parallel to the basement membrane and a loose stroma. Singh et al. indicated different thickness and orientation of collagen fibers in three odontogenic lesions that affect their biological behavior (10).

In the present research, reduced level of TGF- β_1 in aspirated fluid of keratocyst compared with radicular cyst was indicative of decreased formation of collagen and fibrous tissue; therefore, the thickness of collagen fibers would be less and the stroma would be looser in keratocyst, which is in accordance with Singh et al. study (10), showing more aggressive behavior of keratocyst.

Table 4. The relationship between total microvascular density and histological patterns in adenoid cystic carcinoma.

Type of sample	Histological pattern	Total MVD (Mean ± SD)	P- value
Adenoid cystic carcinoma	Tubular	14.2 ± 8.1	0.524
	Cribriform	14.63 ± 6.7	
	Solid	19.5 ± 7.7	

Some research studies have pointed to the efficacy of a number of cyst fluid cytokines in the auxiliary

detection of lesions; although distinguishing keratocyst from radicular cyst is more possible in

terms of clinical aspect, i.e. lack of jaw inflammation and a tendency to anterior-posterior growth, tooth vitality and radiographic view, it seems that in cases of inflammation extended to the mentioned lesions, cytokine levels may change; thus, using cytokine

levels in the detection of inflammatory lesions does not seem to be desirable as it cannot determine whether the inflammation is of primary or secondary origin.

Table 5. The relationship between total microvascular density and grade of differentiation in mucoepidermoid carcinoma.

Type of sample	Grade of differentiation	Total MVD (Mean \pm SD)	P-value
Mucoepidermoid carcinoma	grade I	20 \pm 7.81	0.879
	grade II	18 \pm 5.25	
	grade III	19.38 \pm 7.18	

In a study by Colic et al., the role of inflammatory cytokines such as TNF- α , IL-1 and IL-6 was confirmed in the development of radicular cyst, which is in agreement with the results of the present study (11). In Jurisic et al. research, high levels of TNF- α in radicular cyst was reported to be associated with small size of cysts, higher degree of inflammation and angiogenesis and greater wall thickness by using

ELISA method; however, no relationship has been found between TNF- α expression and inflammation and angiogenesis in keratocyst (12). Likewise, increased grade of inflammation and angiogenesis in radicular cyst and keratocyst has been accompanied with increased level of TNF- α , which is congruent with findings of Jurisic et al. study (12).

Table 6. The relationship between overall microvascular density and five-year survival.

Type of lesion	MVD (Mean \pm SD)	Overall five-year survival rate (month)	P-value
Adenoid cystic carcinoma	16.6 \pm 7.4	52.2 \pm 7.2	0.479
Mucoepidermoid carcinoma	19.11 \pm 6.44	57.3 \pm 8.1	0.091

In an investigation by Piattelli et al., up-regulated TGF- β expression has been reported in basal, suprabasal, superficial epithelium and stromal cell layers of keratocyst in comparison with dentigerous and radicular cysts by using TGF- β_1 immunohistochemical marker in 27 keratocysts, 27 radicular cysts and 28 cases of odontogenic keratocyst (13); the mentioned results are in disagreement with our findings, probably due to difference in the sensitivity of the two methods applied (immune histochemistry and ELISA). No association has been found in the present study in TGF- α and TGF- β_1 levels in fluid aspiration of keratocyst and radicular cyst; however, in Muglali et al. study, a positive relationship has been found in terms of the expression of cytokines such as RANTES, MCP1, TNF- α and IL-1 α in radicular cyst fluid as well as the residuals (14). In Gadbil et al. research, immunohistochemical staining exhibited higher number of blood vessels in keratocyst than radicular and dentigerous cysts and such results might be affected by the type of staining (15). It seems that immunohistochemistry is of more accuracy in the assessment of the number of blood vessels as compared with hematoxylin-eosin. It is conjectured that the difference between the results of different studies might be due to the number and type

of lesions, origin of the lesion (inflammatory or evolutionary), type of cytokine, and approach, accuracy and sensitivity of the study.

Conclusion

Regarding the findings of the present study, it seems that TNF- α and TGF- β_1 are involved in the pathogenesis of radicular cyst and keratocyst. TGF- β_1 level was higher in radicular cyst as compared with keratocyst and a positive association was observed between TNF- α levels and grade of inflammation and angiogenesis in the two lesions.

Acknowledgements

Hereby, the authors would like to thank Dental School of Babol University of Medical Sciences for financially supporting the project, as well as Dr. Ali Bijani and respected personnel of the Cellular and Molecular Research Center, especially Seyed Mohsen Aghajanjpour and Seyedeh Narges Mousavi Kani, for their sincere cooperation.

References

- Johnson NR, Gannon OM, Savage NW, Batstone MD. Frequency of odontogenic cyst and tumors: A systematic review. *J Investing clin Dent*. 2013. PMID: 23766099

2. Sanchez-siles M, Camacho-Alonso F, Lopez-Jornet P, Salazar-Sanchez N. Keratocystic odontogenic tumor. case report and review of literature. NY State Dent J. 2013; 79 (2): 44-7. PMID: 23691729
3. Klapproth JM, Sasaki M. Bacterial induction of proinflammatory cytokines inflammatory bowel disease. Inflamm Bowel Dis. 2010; 16 (12): 2173-90. PMID: 20848533
4. Han B, Qi S, Hu BWJ. TGF-beta i promotes islet beta-cell function and regeneration. J Immunol. 2011; 186 (10): 5833-44. PMID: 21471441
5. Regezi J, Sciubba J, Jordan CK. Oral pathology, chlinical pathologic correlations. 5th Edition. WB Saunders CO; 2008: PP 238-34, 242-43.
6. Ward JP, Magar V, Franks S, Landini G. A. Model on the dynamic of odontogenic cyst growth. Anal Quant cyst Histol. 2004; 26 (1): 39-46. PMID: 15032080
7. Hayashi M, Ohshima T, Ohshima M, Yamaguchi Y, Miyata H, takeichi O, et al. Profilling of radicular cyst and odontogenic keratocyst cytokine production suggests common growth mechanisms. J Endod. 2008; 34 (1): 14-21. PMID: 18155485
8. Jurisic V, Colic S, Jurisic M. The inflamatory radicular cyst have higher concentration of TNF-alpha in comparison to odontogenic keratocyst and odontogenic tumor. Acta Medica. 2007; 50 (4): 233-8. PMID: 18290546
9. Li T, Browne RM, Matthews JB. Immunocytochemical expression of growth factors by odontogenic jaw cysts. Mol Pathol. 1997; 50 (1): 21-7. PMID: 9208810
10. Singh HP, Shetty DC, Wadhwan V, Aggarwal P. A quantitative and qualitative comparative analysis of collagen fibers to determine the role of connective tissue stroma on biological behavior of odontogenic cysts: A histochemical study. Natl J Maxillofac Surg. 2012; 3 (1): 15-20. PMID: 23251052
11. Colic S, Jurisic M, Jurisic V. Pathophysiological mechanism of the developing radicular cyst of the jaw. Actachirlugosl. 2008; 55 (1): 87-92. PMID: 18510067.
12. Jurisic V, Terzic T, Colic S, Jurisic M. The concentration of TNF- α correlation with number of inflammatory cells and degree of vascularization in radicular cysts. Oral Dis. 2008; 14 (17): 600-5. PMID: 18221459
13. Pittelli A, Rubinic C, Fibroni M, Favero L, Strecchi R. Expression of transforming growth factor-beta 1 (TGF-beta 1) in odontogenic cyst. Int Endod J. 2004; 37 (1): 7-11. PMID: 14718051
14. Mugali M, Komerika N, Bulut E, rain GF Celebi N, Sumer M. Cytokine and chemokine levels in radicular and residual cyst fluids. J Oral Pathol Med. 2008; 37 (3): 185-9. PMID: 18251943
15. Gadbil AR, Hande A, Ghaudhary M, nikam A, Gawande M, Puti S, et al. Tumor angiogenesis in keratocysticodontogenic tumor assessed by using CD-105 antigen. J oral pathol Med. 2011; 40 (3): 263-9.